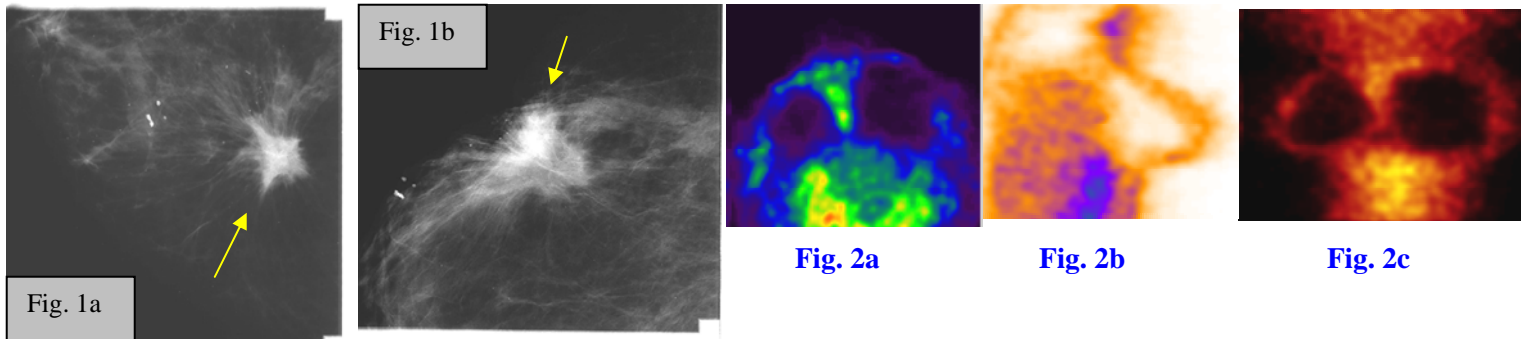


**INTERESTING CASE PRESENTATION**

**PET Scan of the Breasts Distinguishes Cancer from Scar Tissue**



**CLINICAL PRESENTATION:** This 43-year-old female patient presented to the office of **Dr. Arroyo** with a history of lumpectomy/partial mastectomy and axillary node dissection for right breast cancer in 1992, and right breast biopsy in 1999. The mammograms could not differentiate between recurrent cancer and scar tissue in the right breast. The patient was referred to AIC by **Jenét Langjahr, FNP** for a PET scan of the breasts. \*

**PET TECHNIQUE:** The PET scan was performed on AIC's dual-head Siemens E-Cam Plus Nuclear camera/PET scanner. The patient was placed in the **prone** position and was injected with 6 milli-curie (mCi) of FDG (18F-fluoro-deoxy-glucose) in the antecubital vein. The scan was done 2 hours post injection and multiplanar display was rendered.

**MAMMOGRAM FINDINGS:** **Fig. 1a-b** are outside mammograms of the right breast (compression magnification CC and MLO views) showing a large spiculated density (arrows), which can either represent scar tissue or recurrent cancer.

**PET FINDINGS:** **Fig. 2a-c** show the axial, sagittal, and coronal PET scans of the breasts in various color formats. They demonstrate the outline of the breasts with photopenic content. The right breast is smaller than the left due to prior lumpectomy/partial mastectomy. There is no abnormal uptake of FDG in either breasts or in the axillae. These findings are, therefore, compatible with scar tissue in the right breast from prior surgeries and biopsies rather than recurrent cancer.

**CONCLUSION:** **The PET scan has potentially saved this patient an unnecessary biopsy or surgery.** PET scan is also useful in the evaluation of indeterminate breast masses in order to distinguish malignant from benign lesions.

For more information, you may call myself at (661) 949-8111, or Dr. Arroyo or Jenét Langjahr at 949-5833. **If you have an interesting case, please contact me for a clinical-radiological case presentation.**

*Ray Hashemi, MD*

Ray H. Hashemi, M.D., Ph.D., Director

\*Clinical information provided by Dr. Arroyo and Jenét Langjahr. Dr. Arroyo is a family practice physician in Lancaster and Jenét is his family nurse practitioner.

Selec Ref: "PET in breast cancer." Flanagan FL et al., Semin Nuc Med 1998 Oct;28(4):290-302.

"Overview of the current status of PET in breast cancer imaging." Wahl RL. Q J Nuc Med 1998 Mar;42(1):1-7.

"PET in breast cancer: a clinicopathological correlation of results." Rostom AY et al., Br J Radiol 1999 Nov; 72(863):1064-8.

"Innovations in breast cancer imaging: PET for diagnosis and follow-up." Adler LP et al., Medscape Womens Health, 1998 Nov;3(6):5.

"Detection of cancer in augmented breasts by PET." Noh DY et al. Eur J Surg 1999 Sep;165(9):847-51.