

INTERESTING CASE PRESENTATION
Orbital Blowout Fracture

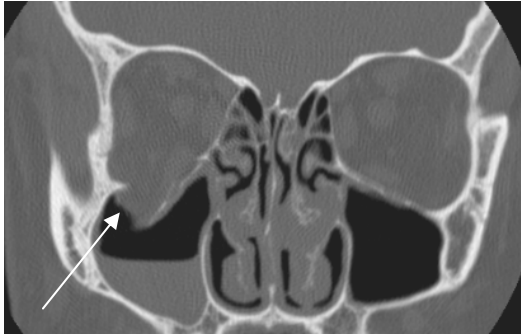


Fig. 1

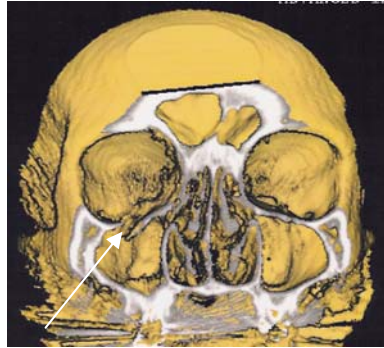

Fig. 2

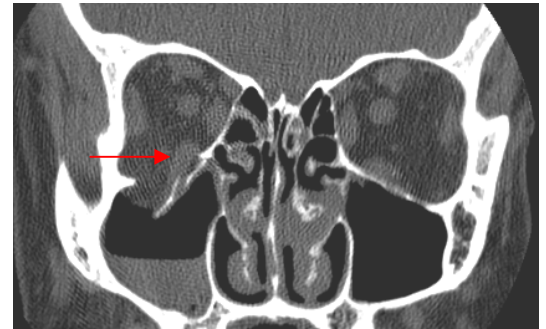

Fig. 3

Clinical Presentation: Patient is a 32-year-old male who presented to **Dr. Ira Opatowsky** after sustaining a punch to the right eye the previous evening. The patient complained of vertical diplopia and hypesthesia of the right cheek. Exam showed normal visual acuity with significant right periorbital edema and 5-7 prism diopter right hypertropia. The patient was referred to AIC by Dr. Opatowsky for a STAT helical CT of the orbits.*

Helical CT Findings: **Figs. 1 and 3** are direct thin coronal sections through the orbits. **Fig. 1** is a bone window and **Fig. 3** is a soft tissue window. **Fig. 2** in the middle is a **3D reconstruction** image performed on an advanced 3D Silicon Graphics workstation with part of the facial bones “cut out” so that one is looking directly inside the orbits and sinuses. They demonstrate fracture of the floor of the right orbit (white arrow) with depression of the orbital floor into the maxillary sinus. An air-fluid level is seen in the maxillary sinus due to presence of hemorrhage. The right inferior rectus muscle (red arrow) is slightly herniated downward (compare to normal left). It is this latter finding that results in diplopia.

Final Diagnosis: The CT findings are typical of a blowout fracture of the right orbit.

Surgical repair: The patient was taken to surgery by Dr. Warren Stout. A transconjunctival approach was used to repair the large orbital floor fracture with a Medpor plate. A large hematoma was evacuated from the maxillary sinus.

Q. What are the clinical symptoms associated with *blow out fractures*?

A. A blowout fracture occurs following direct trauma to the globe that results in increased intraorbital pressure transmitted to the weak orbital floor, often also associated with fracture of the thin lamina papyracea. Orbital floor fracture can produce diplopia (due to entrapment of inferior rectus +/- inferior orbital tissues or inferior rectus palsy), cosmetically objectionable enophthalmos (due to posttraumatic atrophy of orbital fat), and facial anesthesia. Smaller fractures may not require surgery.

For more information, you may call myself at (661) 949-8111 or Dr. Opatowsky at 948-4373. **If you have an interesting case, please contact me for a clinical-radiological case presentation.**

Ray Hashemi, MD

Ray H. Hashemi, MD, PhD, Director

*Clinical information provided by **Dr. Opatowsky**. He is a comprehensive ophthalmologist and the medical director of AV eye care in Lancaster. He can be reached at (661) 948-4373.